

Chest X-ray Review

Chest x-ray review is a key competency for medical students, junior doctors and other allied health professionals. Chest radiographs are frequently performed and a fantastic tool for making diagnoses of acute and chronic conditions, as well as acting as a tool for follow up.

Be systematic

There are many systematic ways to review a chest x-ray. The important thing is to get into the habit of having a systematic approach. If you do the same thing every time you look at a chest x-ray, you will be much less likely to make a mistake.

Initial review

Start off the same way each time you look at a film. Every time you look at an x-ray or other scan, think about:

- who, what, why, where and when
- quality

When looking at chest x-rays, also think about:

- lines and tubes

Who, what, why, where, when

Whenever you look at any imaging, ask:

- **who** does it pertain to? (John Smith 12 Jan 1952)
- **what** are you looking at? (PA chest x-ray)
- **why** was it done? (Increased shortness of breath)
- **where** was it done? (Emergency)
- **when** was it performed? (21 Jun 2017)

Quality

Assessment of the quality of a radiograph allows you to make an assessment about what can be diagnosed using the study. If a chest radiograph is under-inspired and rotated, it is of limited diagnostic use.

- rotation: medial ends of the clavicles equidistant from the spinous processes
- inspiration: 10 to 11 posterior ribs on left side

Lines and tubes

The first thing to look at when reviewing a chest x-ray is any additional line or tube on the film. There will often be ECG leads and in some patients, other devices, e.g. pacemaker. Note the position of ET and NG tubes, chest drains or central lines. The fact that these tubes and lines are present gives you additional information about how sick the patient is.

- ET tube placement
- NG tube placement
- CVC placement

❖ ET tube placement

Endotracheal tube placement is frequently assessed using chest radiography. In adults, the tip of the ET tube should be approximately 5 cm from the carina (approximately halfway between the interclavicular line and the carina).

Changes in position

The position of the ET tube tip is dependent on the position of the head. Most people think that neck flexion will result in elevation of the ET tube tip. However, neck flexion results in depression of the ET tube tip. Conversely, extension of the neck results in elevation of the ET tube tip. Tip position may change by up to 2 cm up or down from neutral position.

Radiographic appearances

Normal

- tip 5 cm above carina
- width 2/3 tracheal diameter
- cuff should not expand the trachea

Malposition

When ET tubes are malpositioned, they most frequently find their way into the right main bronchus with resultant left lung collapse.

❖ NG tube placement (Fig.1)

NG tube placement (nasogastric tube) is commonly assessed using a chest radiograph although local protocol may dictate that pH assessment of NG aspirate be used in the first instance to confirm position of the NG tube.

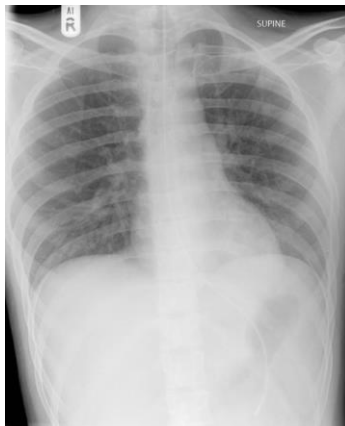There are recognised landmarks to look for on chest radiograph which can help you confirm NG tube placement:

- tube goes down the thorax in the midline
- tube bisects the carina
- tube crosses the diaphragm in the midline
- the tip sits below the diaphragm

By following these guides, the likelihood of the tube following the path of an *airway* rather than the oesophagus is low.

Most feeding tubes should be visible on a plain film without a guidewire. If you have trouble seeing the landmarks, you can change the windowing of the radiograph, discuss with a senior or consider repeating the film (in discussion with your radiographers).

Correct interpretation is important to get right because of the potential consequences if the tube is misplaced.



(Fig1)

Correct placement of nasogastric tube.

❖ CVC placement

A, B, C, D, E

One of the easiest systems for reviewing a chest x-ray is A, B, C, D, E (using the same headings as ALS (advanced life support)):

- **A:** airway
- **B:** breathing (lungs and pleural spaces)
- **C:** circulation (cardiomediastinum)
- **D:** disability (fractures and dislocations)
- **E:** exposure (everything else)

Airway (airways) (Fig.2a,b,c)

The airways are often overlooked

- start at the top and follow the trachea down in the midline to the carina
- trace the right and left main stem bronchi
- the angle between the left and right mainstem bronchi shouldn't be much more than 90 degrees

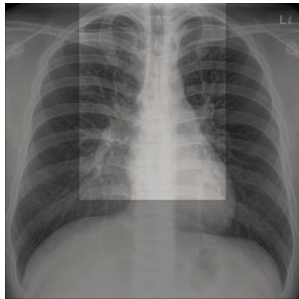


Fig2a

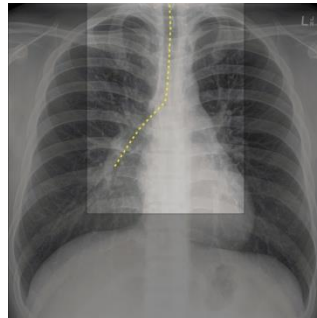


Fig2b Trace down the trachea in the midline and continue down the right main bronchus

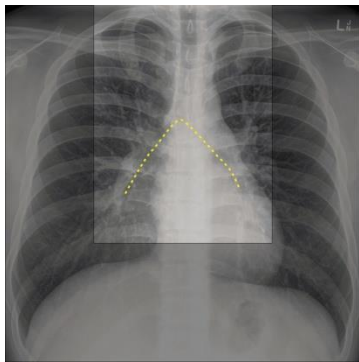


Fig2c Trace across the carina and down the left main bronchus

Breathing (lungs and pleural spaces) Fig.4(a-h)

- compare each size in all 4 zones looking for altered density or focal mass lesions
- check around the lungs starting laterally, from the apex down to the costophrenic angle
 - does the lung extend to the chest wall
 - is there a pneumothorax?
- check both costophrenic angles
 - is there an effusion?
- ensure you can trace the hemidiaphragms to the spine
- check the cardiac borders up to the hilar structures

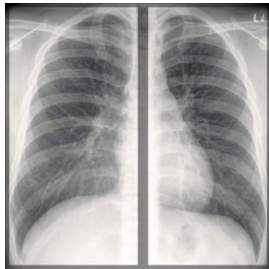


Fig4a

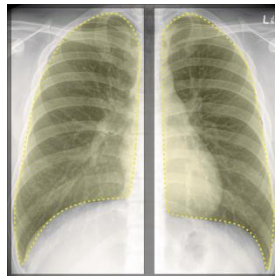


Fig. 4 b Check that both lungs are of similar volume (allowing for mediastinal asymmetry).

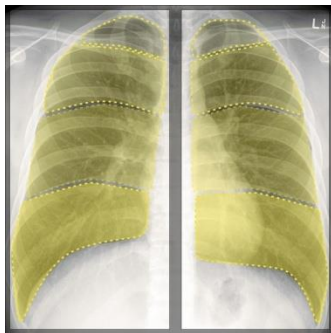


Fig. 4 c Review each zone in turn, comparing it to the other side. Look for collapse, consolidation or masses.

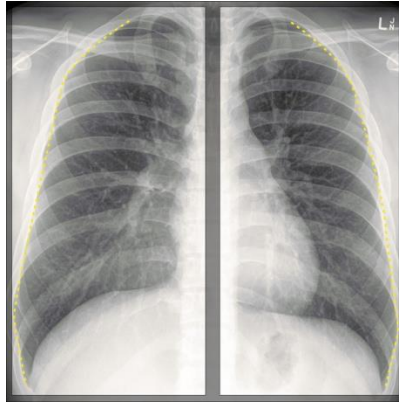


Fig. 4 d Check around the lateral margin of each lung; markings should extend to the edge.

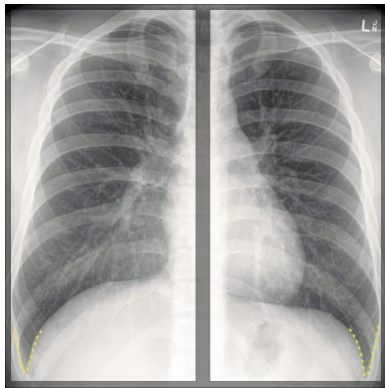


Fig. 4 e Check each costophrenic angle; they should both be crisp

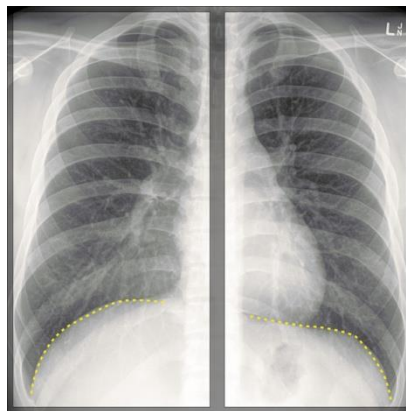


Fig. 4 f Check the hemidiaphragms; they should be visible and crisp all the way to the vertebral bodies

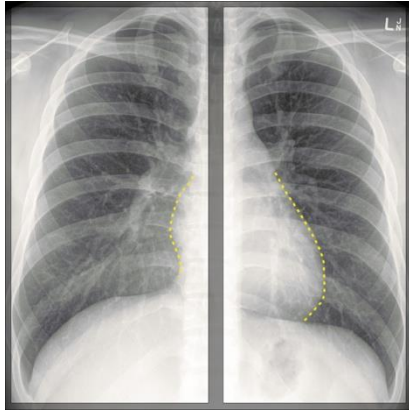


Fig. 4 g Check the cardiac borders; they should be crisp and well-defined

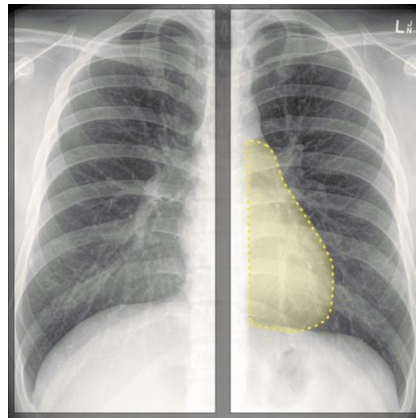


Fig. 4 h Check behind the heart

Chest radiograph zones (Fig. 3)

The **chest radiograph zones** are useful when describing the location of pathology on a frontal chest radiograph.

The chest radiograph is a 2D representation of a 3D structure. Since the interfaces between the lobes are orientated obliquely, it is often not possible to determine which lobe pathology is located in or whether it is located anteriorly or posteriorly. Hence, describing the location of pathology using the four-zone technique is helpful:

- [apical zone](#) - above the clavicles
- [upper zone](#) - below the clavicles and above the cardiac silhouette
- [mid zone](#) - the level of the hilar structures
- [lower zone](#) - the bases

It is recommended to use the zones loosely while reporting as the distinctions are arbitrary and do not correspond to anatomic structures.

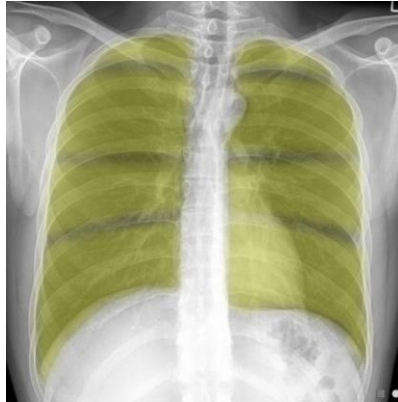

Fig3 Normal CXR - 4 zones highlighted

Apical zone [\(Fig. 3a\)](#)

The **apical zone** is one of the four chest radiograph zones and an important location for missed diagnoses when reporting a frontal chest radiograph and makes up on the "check areas". It is sometimes thought of as a subdivision of the upper zone.

Radiographic appearance

Plain film

- portion of the lungs that lie above the inferior margin of the clavicles on a frontal chest radiograph

Related pathology

The apices and upper zones are preferentially affected by pathology that is related to inhalation. The upper portion of the lungs have a positive ventilation mismatch when compared to the bases, where there is preferential perfusion. Common conditions involving the apical zone includes:

- sarcoidosis
- allergic bronchopulmonary aspergillosis (ABPA)
- extrinsic allergic alveolitis
- pulmonary tuberculosis
- radiotherapy changes

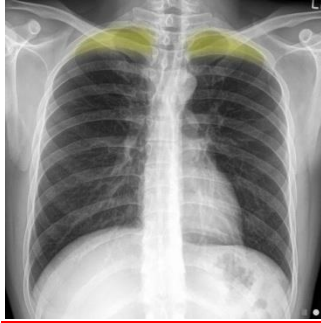

Fig3a Normal CXR - apical zones highlighted

Upper zone (Fig. 3b)

The **upper zone** is one of the four chest radiograph zones. Sometimes the upper zone includes the apical zone.

Radiographic appearance

Plain film

- on frontal chest radiographs, the upper zone extends from the inferior margin of the clavicles to the superior aspect of the hilum

Related pathology

pulmonary upper zone involvement (mnemonic).

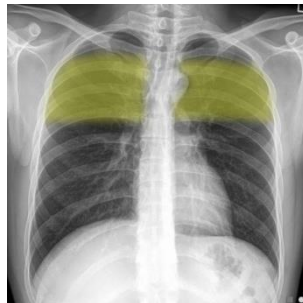


Fig3b Normal CXR - upper zones highlighted

Mid zone [\(Fig. 3c\)](#)

The **mid (or middle) zone** is one of the four chest radiograph zones.

Radiographic appearance

Plain film

- on frontal chest radiographs, extends between the superior and inferior aspects of the hilum

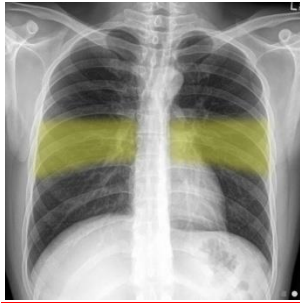

Fig3c Normal CXR – mid zones highlighted

Lower zone [\(Fig. 3d\)](#)

The **lower zone** is one of the four chest radiograph zones.

Radiographic features

Plain films

- on frontal chest radiographs, extends inferiorly from the inferior aspect of the hilum to the hemidiaphragm

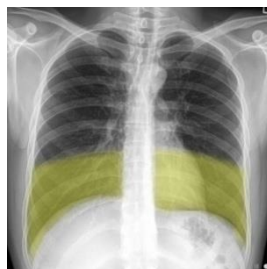


Fig3d Normal CXR – lower zones highlighted

Circulation (cardiomediastinum) (Fig.5 a-f)

Assessment of the mediastinum is predominantly about looking at the heart, but it is imperative to remember the other structures in the mediastinum.

Assess the size of the heart, review the aortic knuckle and the upper mediastinal contour. After that, check the pulmonary vessels and the hilar structures. The left hilum is usually higher than the right.

The final thing to look for is a hiatus hernia with a retrocardiac fluid-fluid level.

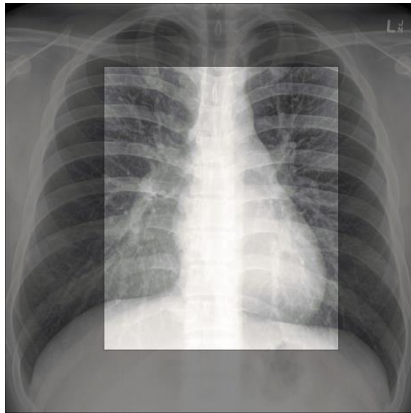


Fig5a

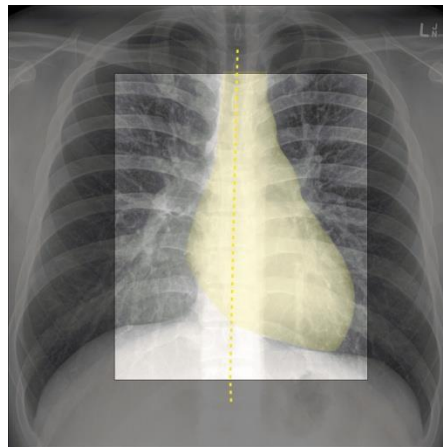


Fig. 5 b

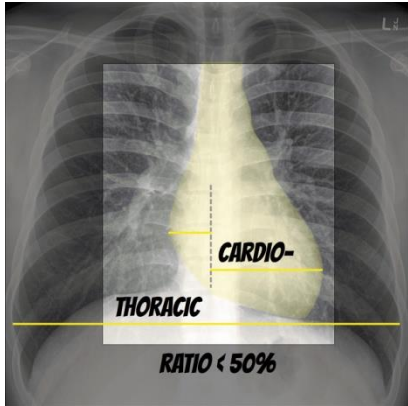


Fig. 5 c

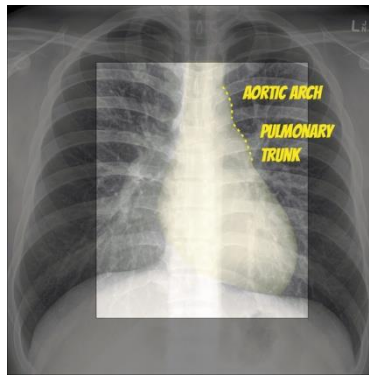


Fig. 5 d

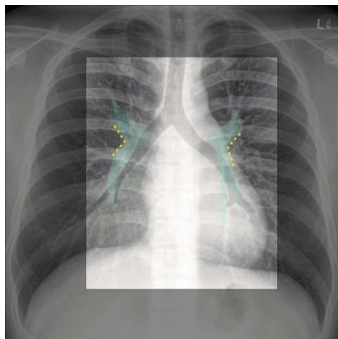


Fig. 5 e

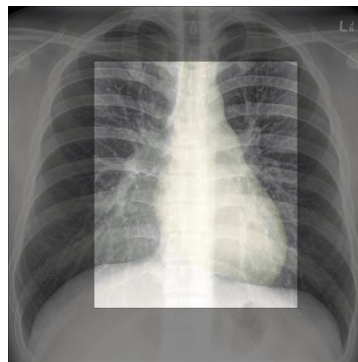


Fig. 5 f

Disability (fractures)

Check the bony thorax, especially the ribs for any evidence of fracture. If the shoulders have been included on the film, check the glenohumeral joints and the clavicles.

Exposure (everything else)

At the end of the review, you need to remember to check for other things that don't fall into the A-D categories. This includes free gas within the abdomen (pneumoperitoneum), abnormalities in the soft tissues of the thorax including surgical emphysema and absent breast shadows.

Review areas

Double-check the apices (masses, pneumothorax), hila (masses, lymphadenopathy), retrocardiac zone (lobar collapse, hiatus hernia) and below the diaphragm (tubes and free air).

Finally, always compare to old films.

Prepared by: Dr. Sameh Momen

References: www.radiopaedia.org