

Laboratory complete denture prosthodontics

Collected and organized by

Prof. Ahmad Elshimy

Head and Professor of Prosthodontics
Removable prosthodontics department
Faculty of Dentistry
Alexandria University Egypt.

Dr. Nayrouz Adel Metwally

Assistant lecturer of Prosthodontics
Removable prosthodontics department
Faculty of Dentistry
Alexandria University Egypt.

Second Year

2018-2019



Acknowledgments

This two-year curriculum was developed through a participatory and collaborative approach between the Academic faculty staff affiliated to Egyptian Universities as Alexandria University, Ain Shams University, Cairo University , Mansoura University, Al-Azhar University, Tanta University, Beni Souef University , Port Said University, Suez Canal University and MTI University and the Ministry of Health and Population (General Directorate of Technical Health Education (THE)). The design of this course draws on rich discussions through workshops. The outcome of the workshop was course specification with Indented learning outcomes and the course contents, which served as a guide to the initial design.

We would like to thank **Prof. Sabah Al- Sharkawi** the General Coordinator of General Directorate of Technical Health Education, **Dr. Azza Dosoky** the Head of Central Administration of HR Development, **Dr. Seada Farghly** the General Director of THE and all share persons working at General Administration of the THE for their time and critical feedback during the development of this course.

Special thanks to the **Minister of Health and Population Dr. Hala Zayed** and **Former Minister of Health Dr. Ahmed Emad Edin Rady** for their decision to recognize and professionalize health education by issuing a decree to develop and strengthen the technical health education curriculum for pre-service training within the technical health institutes.

The logo of the Ministry of Health & Population of Egypt is a large, circular emblem. It features a central blue circle containing a stylized white figure of a person with arms raised. Above this figure is a smaller circle with a yellow sun-like symbol. The entire emblem is set against a light blue background. The text "Ministry of Health & Population" is written in a semi-circle below the central figure. At the bottom, the Arabic name "وزارة الصحة والسكان" is written in white on a red background.

Ministry of Health & Population
وزارة الصحة والسكان

Contents

Course Description	vii
Course overview	viii
Chapter 1: INTRODUCTION	1
Chapter 2: Anatomical Landmarks	9
Chapter 3: Impression Trays and Materials	16
Chapter 4: Record blocks and Mounting	25
Chapter 5: Articulators	29
Chapter 6: Arrangement of artificial teeth	34
Chapter 7: Complete denture processing	41
References and Recommended Readings	47

Ministry of Health & Population
وزارة الصحة والسكان

Course Specifications

توصيف مقرر دراسي

1- بيانات المقرر		
الرمز الكودي :	اسم المقرر :	الفرقة / المستوى : الثانية
	Laboratory Complete Dentures Prosthodontics	
التخصص :	عدد الوحدات الدراسية :	نظري 3 عملي 12

2- Overall Aim of Course:	The course includes the preclinical procedures for complete denture construction and their interdependence procedures will be stressed. The candidate should learn the basic principles of clinical removable prosthodontics treatment for completely edentulous patients, and the different laboratory steps for complete denture construction.
هدف المقرر	

3- Intended learning outcomes of the course (ILOs):	3 - المستهدف من تدريس المقرر
---	------------------------------

i. Knowledge and Understanding:	<u>By the end of this course, students should be able to:</u> a1.list the anatomical landmarks of completely edentulous arch. a2-Describe the different types of articulators. a3-Define flasking ,packing and curing. a4-Describe how to repair fractured complete and RPD a5-Outline the responsibilities of both technician and dentist. a6-Trace new trends of complete denture.
ا. المعلومات والمفاهيم :	

ii. Intellectual Skills:	By the end of this course, students should be able to: b1-Interpret technical factors that cause failure of complete denture. b2- Evaluate the technical work. b3-Select suitable materials and technique to use.
ب- المهارات الذهنية :	

III. Professional Skills:	<u>By the end of this course, students should be able to:</u> c 1-Apply the specified procedures for removable denture construction with professional applications c2-Choose the suitable material and technique. c3_Practice the arrangement of anterior teeth
ج- المهارات المهنية الخاصة بالمقرر:	

	<p>c4-practice the arrangement of the posterior teeth and occlusal adjustment.</p> <p>c5-apply falsking ,packing and curing.</p> <p>c6-pratice finishing and polishing of the dentures.</p>
<p>IV. General and Transferable Skills:</p> <p>د- المهارات العامة :</p>	<p><u>By the end of this course, students should be able to:</u></p> <ol style="list-style-type: none"> 1. Assess problems. 2. Work efficiently with others. 3. Practice independent learning by using information technology tools. 4. Evaluate information from various standard sources to improve professional skills.
<p>4- Course content</p> <p>4- محتوى المقرر:</p>	<ol style="list-style-type: none"> 1.Introduction & regulations of the course. 2. Anatomical landmarks of edentulous jaws. 3. Impression trays and materials. 4.Record blocks and Mounting. 5. Articulators . 6. Mounting. 7.Arrangement of artificial teeth in different occlusal schemes occlusion. 8. Steps of complete denture processing. 9.Lab Remount.
<p>5- Teaching and Learning Methods:</p> <p>5- أساليب التعليم والتعلم</p>	<ol style="list-style-type: none"> 1. Lectures. 2. Group discussions 3. Practical cessions
<p>6- Teaching and learning methods for students with limited abilities</p> <p>6 - أساليب التعليم والتعلم للطلاب ذوي القدرات المحدودة</p>	
<p>7- Student Assessment:</p> <p>7- تقويم الطلاب :</p>	
<p>a- Assessment methods:</p> <p>أ- الأساليب المستخدمة</p>	<p>a. Class work:</p> <ol style="list-style-type: none"> 1. Quizzes 2. Midterm theoretical 3. Practical exam 4. Assignments 5. Participation <p>b. Final exam:</p> <p>Written theoretical</p>

b- Assessment schedule: ب- التوقيت	a. Class work: 1. Quizzes: Quiz I (4 th week) Quiz II (11 th week) 2. Midterm theoretical (7 th week) 3. Assignments 4. Participation b. Final exam Practical exam (13 th week) written theoretical exam (15 th week)
C-Weight Of Assessments: ج- توزيع الدرجات	1. Quizzes and class work (15%), 15 marks 2. Practical (15%), 15 marks. 3. Final written theoretical exam (70%), 70 marks. Total percentage 100%
7- List of References: 8- قائمة الكتب الدراسية والمراجع :	
a- Course notes: أ- مذكرات	Lecture and practical notes for GMP
b- Essential books (text books) ب- كتب ملزمة	- Winkler S. Essentials of complete prosthodontics, Third Edition. WB Saunders Company, 2003. - Zarb GA, Blender CL, Carlson GE. Boucher's Prosthodontics treatment for edentulous patients, Eleventh Edition. St Louis; CV Mosby CO, 1997.
c- Recommended books ج- كتب مقترحة	- Rahn AO, Heartwell CM. Textbook of complete dentures. Fifth Edition. Philadelphia ; Lea and Fibiger, 1993.
d- Periodicals, web sites, د- دوريات علمية أو نشرات الخ	• www.qualitysafety.bmj.com • www.google.com • www.pubmed.com • www.biomed.net

Course Description

The course includes the preclinical procedures for complete denture construction and their interdependence procedures will be stressed.

The candidate should learn the basic principles of clinical removable prosthodontics treatment for completely edentulous patients, and the different laboratory steps for complete denture construction. They will also gain practical experience by applying the knowledge gained during the first academic year to better understand their audience and create more effective laboratory work.

Core Knowledge

By the end of this course, students should be able to:

- List the anatomical landmarks of completely edentulous arch.
- Describe the different types of articulators.
- Describe how to repair fractured complete and RPD
- Define flasking ,packing and curing.
- Outline the responsibilities of both technician and dentist.
- Trace new trends of complete denture.

Core Skills

By the end of this course, students should be able to:

- Interpret technical factors that cause failure of complete denture.
- Evaluate the technical work.
- Select suitable materials and technique to use.
- Apply the specified procedures for removable denture construction with professional applications
- Choose the suitable material and technique.
- Practice the arrangement of anterior teeth
- practice the arrangement of the posterior teeth and occlusal adjustment.
- Apply falsking ,packing and curing.
- Practice finishing and polishing of the dentures.

- Assess problems.
- Work efficiently with others.
- Practice independent learning by using information technology tools.
- Evaluate information from various standard sources to improve professional skills.

Course Overview

ID	Topics	Methods of Teaching/ Training with Number of Total Hours per Topic				
		Interactive Lecture	Field Work	Class Assignments	Research	Lab
1	Anatomical landmarks of edentulous jaws.	5			3	16
2	Impression trays and materials.	6			2	20
3	Record blocks and Mounting.	5		√	1	15
4	Articulators .	5			1	20
6	Arrangement of artificial teeth	5			1	24
7	Steps of complete denture processing.	5		√	1	24
8	Steps of complete denture processing.	5			1	15
TOTAL HOURS (180)		36			10	134

Chapter 1

INTRODUCTION

Objectives

- Provide an overview of the prosthodontics(Prosthetic dentistry)
- Define the prosthodontics terms and main concepts.
- Objectives of complete denture prosthodontics.
- Denture components.
- Steps of construction of complete denture

An overview of the prosthodontics (Prosthetic Dentistry)

Prosthesis

An artificial replacement of an absent part of the human body.

Prosthetics

The art and science of supplying artificial replacement for missing parts of the human body.

Prosthodontics (Prosthetic dentistry)

The branch of dentistry that deals with the replacement of missing dental and oral and craniofacial structures.

Removable prosthodontics

It is devoted to replacement of missing teeth and contiguous tissues with prostheses designed to be removed by the wearer. It includes two disciplines: removable complete and removable partial prosthodontics.

Maxillofacial prosthodontics

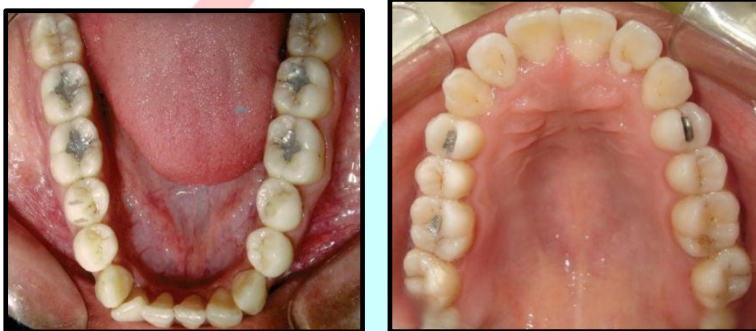The branch of prosthodontics concerned with the restoration and/or replacement of the stomatognathic and craniofacial structures with prostheses that may or may not be removed on a regular or elective basis.

Prosthodontist

A specialist in prosthodontics.

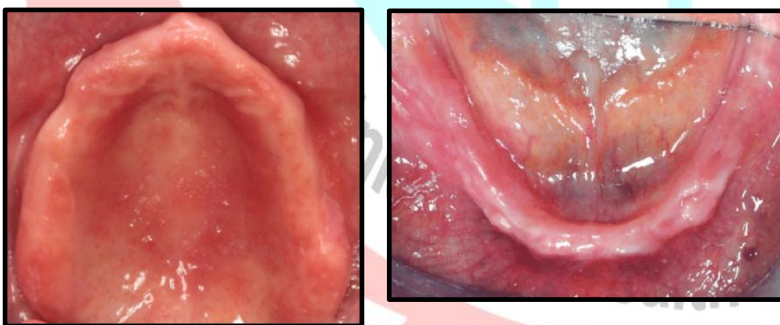
Dentulous (adj.)

A condition in which complete set of natural teeth are present in the mouth.



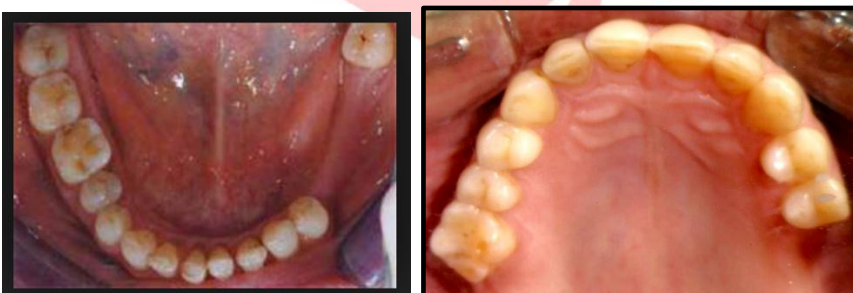Edentulous (adj.)

A condition in which the mouth is without teeth.



Partially edentulous

A condition in which some of the natural teeth are lost.

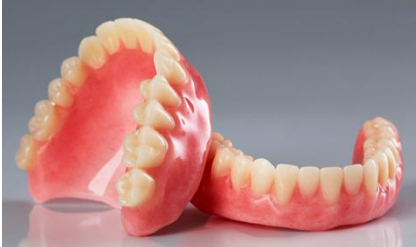

Denture

An artificial substitute for missing natural teeth and adjacent tissues.

Complete Denture

A removable dental prosthesis that replaces the entire dentition and associated structures of the maxillae or mandible.

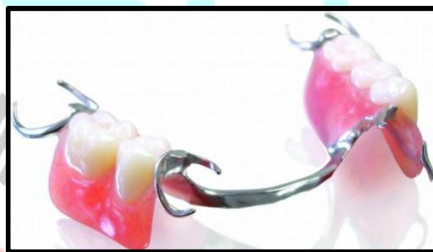
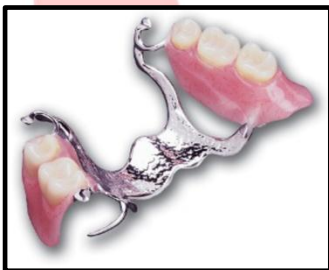
Partial denture

A dental prosthesis that restores one or more but not all of the natural teeth and/ or associated parts and that is supported in part by natural teeth, dental implant supported crowns, abutments, or other fixed partial dentures and or the mucosa. It may be fixed or removable.

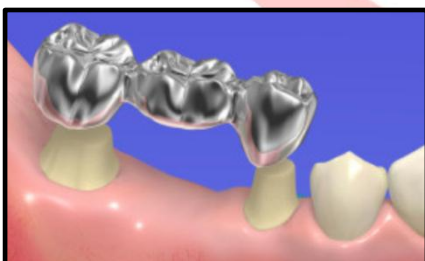
Removable partial denture

A partial denture that can be removed and replaced from the mouth.



Fixed partial denture

A partial denture that is cemented to natural teeth or tooth roots and/or dental implants.



Immediate denture

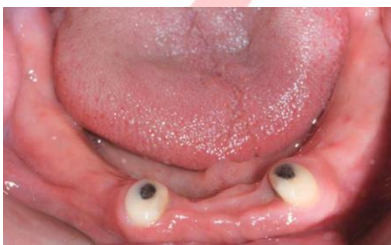A complete denture or removable partial denture fabricated for replacement immediately following the removal of natural teeth.

Single complete denture

A single denture is a complete denture that occludes against some or all of the natural teeth, a fixed restoration, a previously constructed removable partial denture or complete denture.

Over Denture

A removable partial or complete denture that covers and rests on one or more remaining natural teeth, roots, and/ or dental implants.

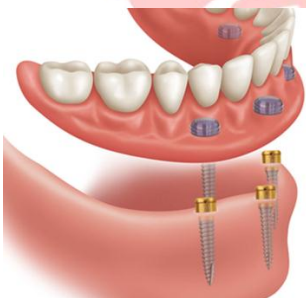


Implant prosthesis

Any prosthesis (fixed or removable or maxillofacial) that utilizes dental implants in part or whole for retention, support, and stability

Dental implant

A prosthetic device of alloplastic material implanted into the oral tissues beneath the mucosal and/or periosteal layer and/or within the bone to provide retention and support for a fixed or removable prosthesis.



Obturator

A prosthesis used to close a congenital or acquired tissue opening, primarily of the hard palate and/or contiguous alveolar structures.

Retention

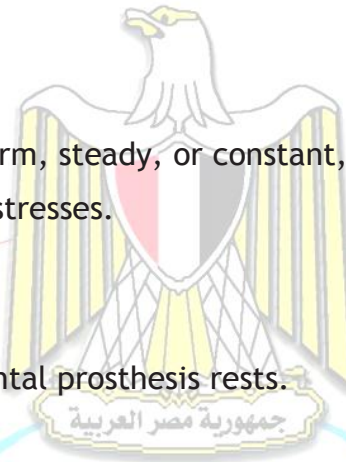
That quality inherent in the prosthesis acting to resist the forces of dislodgment along the path of placement.

Stability

That quality of a prosthesis to be firm, steady, or constant, to resist displacement by functional horizontal or rotational stresses.

Support

The foundation area on which a dental prosthesis rests.



Objectives of denture prosthetics:

It is difficult to say which of the three functions restored by complete denture, mastication, speech, or esthetics, is most important. Even though each patient has different ideas as to what a denture should be, the dentist attempts to restore all of these functions and to do it in such a way that the patient is comfortable and the supporting tissues are preserved as possible.

1- Restoration of masticatory efficiency

Teeth are necessary for good digestion and optimal health. Chewing makes eating more enjoyable. Chewing of food and mixing it with saliva is also the first step in digestion.

2- Restoration of facial contour and appearance

A properly constructed denture will correct and restore the patient's normal appearance. In addition to soft tissue changes, loss of natural teeth leads to resorption of the alveolar bone, the improper placement of artificial teeth without consideration of the bony changes will result in improper support of the lips and an unnatural esthetic result.

3- Correction of speech defects

Effective speech requires teeth. The tongue contacting or valving against the teeth forms many sounds. Proper placement of artificial anterior and posterior teeth is necessary to restore good speech.

4.Preservation of the remaining tissues

The alveolar process that developed with the teeth for the purpose of supporting them disappears to a varying extent after loss of teeth, resulting in reduced alveolar ridge. Restoration of the chewing function through dentures minimizes the rate of alveolar atrophy. With the loss of teeth, the joints are subjected to continuous temporo- mandibular strains because the mandible closes in abnormal position

5.Patient satisfaction and comfort

No dental prosthesis can function satisfactorily if it causes discomfort. An un- comfortable patient is unhappy. It must be recognized that a patient has to accept the dental prosthesis psychologically in order to be comfortable.

Components of complete denture:

Complete dentures consist of :

Denture base which is the part of the denture that rests on the supporting structures and to which teeth are attached.

Function of the base

- 1- to provide the retention and stability of the denture.
- 2- to carry and support the teeth.
- 3- to represent the gums.
- 4- to assist the teeth in supporting the cheeks and lips.

Artificial teeth attached to the base.

Function of the teeth

- 1- to assist in preparing food for deglutition.
- 2- to provide a pleasing and natural appearance. 3- to assist in speech.

Complete denture has 3 surfaces :

- A) Fitting surface : is the denture surface that is determined by the impression.
- B) Polished surface : is the surface that starts from the borders of the denture and includes the facial (labial and buccal), lingual and palatal surfaces facing the cheeks, lips and tongue.
- C) Occlusal surface: is the surface which makes contact with its antagonist.

Denture borders

The margins of the denture base at the junction of the polished and impression surface.

Denture flange

Is the vertical extension of the denture base that extends from the cervices of the teeth to the borders of the denture flanges they are named according to location :

- . A) Labial flange : The portion of flange that occupies the labial vestibule.
- . B) Buccal flange: The portion of the flange that occupies the buccal vestibule.
- . C) Lingual flange: The portion of the flange of the mandibular denture that occupies the alveololingual sulcus.

Steps of construction of complete denture:

Clinical steps	Laboratory steps
1. Examination of the patient	
2. Primary impression	a- Pouring the impression and preparation of the study cast (from plaster), b- Construction of custom tray.
3. Final impression (custom tray)	Pouring master cast (from stone plaster). Construction of record blocks.
4. Recording jaw relations Selection of teeth	Mounting the casts on the articulator. Arrangement of artificial teeth. Wax contouring.
5. Trying in the denture.	Flasking. Wax elimination. Packing of acrylic resin. Curing. Laboratory remount. Finishing and polishing
6. Denture insertion Instructions to the patient Clinical remount	
7. Post insertion care.	

Chapter 2

Anatomical Landmarks

Objectives

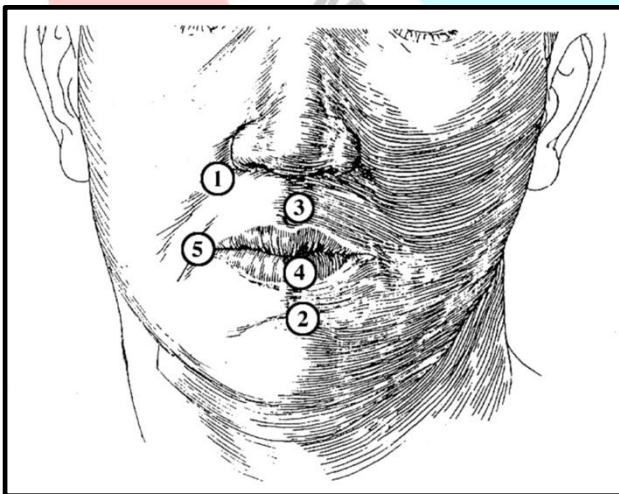
- Extraoral landmarks of prosthetic importance.
- Intraoral landmarks of prosthetic importance
- Border Structures that Limit the Periphery of the denture.

Extraoral landmarks of prosthetic importance:

A patient's face provides the dentist with a considerable amount of information. Prolonged edentulous periods result in apparent changes in the lower third of the face.

1. Nasolabial sulcus:

This is the crease that extends laterally and downwards from the ala of the nose to the corners of the mouth. It becomes more prominent with aging .



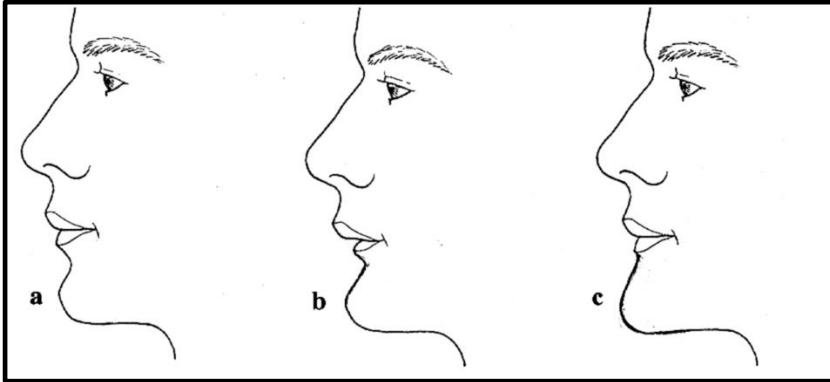
2. Mentolabial sulcus

This runs from side to side horizontally between the lower lip and chin. Its curvature frequently indicates the character of the maxillo mandibular relationship.

In normal ridge relationship (Angle class I) the mentolabial sulcus shows a gentle curvature which represents an obtuse angle.

In angle class II the mentolabial sulcus presents an acute angle in which the lower lip is folded towards the chin.

In angle class III the mentolabial sulcus may form an angle of 180°



3. Philtrum : (Filtrum)

This is a diamond shaped area at the center of the upper lip and base of the nose. With the loss of teeth and labial alveolar bone it becomes flattened. Improper tooth alignment may obliterate the filtrum. While a proper denture with appropriate arch form frequently restores a good contour to the filtrum within a short time.

4. Vermillion border

It is the transitional epithelium between the mucous membrane of the lips and the skin, the amount of vermillion border shown on the lips depends on :

- a) The bulk of the orbicularis oris muscle.
- b) The amount of the labial alveolar bone.
- c) The alignment of teeth.

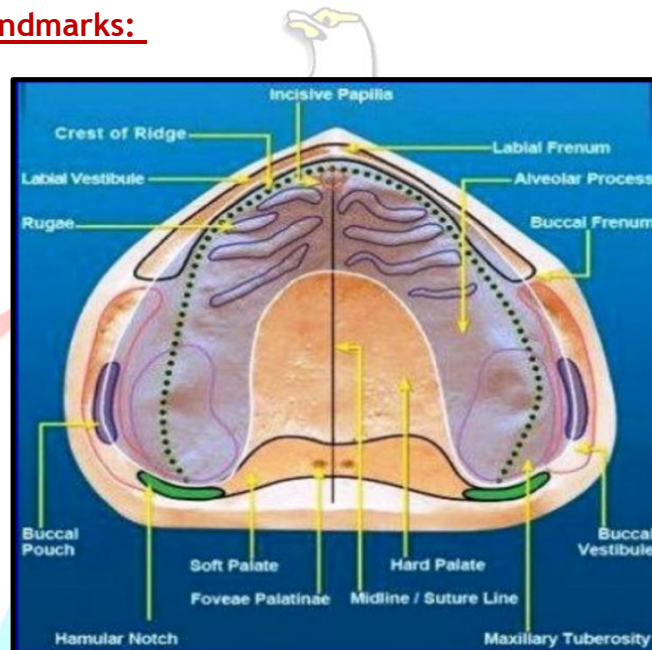
5. Angle of the mouth (commisure):

Dentures should support the mouth angle, because lack of proper support of the upper lip may cause angular chielitis that is fissuring and inflammation of the angle of the mouth as a result of continuous wetting from saliva and a reduced vertical dimension.

Intraoral landmarks of prosthetic importance:

After extraction of teeth, the alveolar bone that supports the teeth begins to resorb and decrease in size. The part of the alveolar process that remains is called the residual ridge.

Maxillary anatomical landmarks:



1. Alveolar ridge

It is the portion of the alveolar process and its soft tissue covering that remains after the extraction of teeth. The residual ridge considered the primary stress bearing area in the upper jaw.

2. Maxillary tuberosity

Distal to the maxillary third molar, the alveolar process ends in a prominence that is called the maxillary tuberosity. It is a rounded bulge behind and slightly above the distal end of the residual maxillary ridge.

3. Hamular or pterygo maxillary notch

It is depression distal to the maxillary tuberosity used as a landmark for the correct extension of the upper denture.

4. Palatine vault

This is formed anteriorly by the hard palate and posteriorly by the soft palate.

5. Median palatine raphe

The hard palate is formed by the pre- maxilla and two palatine processes of the maxillary bone. The suture that joins the two palatine processes at the midline is called the midpalatal suture. Its position in the palate is marked with a raised area of mucous membrane called the median palatine raphe, which may be hard or sensitive. It is generally relieved to prevent the upper denture from rocking.

6. Incisive papilla

This is a pad of fibrous connective tissue overlying the orifice of the nasopalatine canal. It is located on the palatal side and between the necks of the central incisors. In some cases due to excessive bone resorption, after loss of natural teeth, the papilla may lie on the crest of the ridge. In this condition it may require relief in the upper denture to avoid pressure on the incisive nerve and vessels, pressure on the nerve may cause burning sensation.

7. Rugae

These are irregularly shaped ridges of connective tissues covered by mucous membrane in anterior third of the hard palate. The rugae are thought by some to play a part in speech, especially the letter “s”.

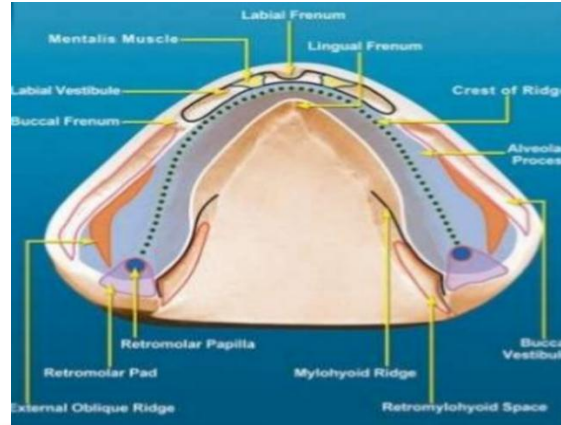
8. Torus palatinus

There is usually a raised, bony ridge running down the center of the hard palate from the anterior palatine foramen to the posterior border, or any part of this distance, which is known as torus palatinus. If the size of the torus is too big or extended posteriorly to where the posterior palatal seal is placed, it should be surgically removed. If the torus is small, the denture base over this area must be relieved.

9. Fovea palatinae

These are small pits or indentations which are found at the midline just posterior to the junction of the hard and soft palate. They are openings of ducts of minor salivary glands.

Mandibular anatomical landmarks :



1. Alveolar ridge

Like in the maxilla it is the part of the alveolar process and its soft tissue covering that remains after extraction of teeth. The highest continuous surface of the ridge is the crest of the ridge.

2. Retromolar pad

It is a pear shaped area found on each side of the distal end of the residual mandibular ridge. The retromolar pad is used as a guide for locating the position of the occlusal plane of the mandibular denture. Which must not be higher than half its vertical height

3. External oblique ridge

It is a ridge of dense bone extending from just above the mental foramen superiorly and distally, then becomes continuous with the anterior border of the ramus of the mandible.

4. Buccal shelf area :

It is bounded externally by the external oblique ridge and internally by the slope of the residual ridge. The bone in this area is very dense and the trabeculation is arranged almost at right angle to the path of jaw closure.

5. Mental foramen

It is located on the buccal surface of the mandible in the premolar region between the roots of the first and second premolars. The mental nerves and vessels pass through it.

6. Torus mandibularis

It is a bony projection sometimes found on the inner surface of the mandible in the premolar region. It may be unilateral or bi-lateral. It is covered by a thin mucous membrane, where relief of the lower denture in this area will be necessary. When the torus mandibularis is large, and interfere with the seating of denture, it should be removed surgically.

Stress bearing areas

A. Primary stress bearing areas

Primary stress bearing areas are those areas which are able to resist the vertical forces of occlusion, they are formed of cortical bone protected by firmly attached mucous membrane.

In the maxillary arch and palate:

- The crest of the ridge.
- The flat areas of the palate

In the mandibular arch:

- The buccal shelf of bone.
- The crest of the ridge if it is well formed.

B- Secondary stress bearing areas

Secondary stress bearing areas are those areas which by their histological nature and their inclined planes, resist the lateral forces of occlusion and can aid in the resistance to the vertical forces.

In the maxillary arch:

- 1- Lateral slopes of the palate
- 2- Rugae area.
- 3- Labial and buccal surfaces of the ridge.

In the mandibular arch :All ridge slopes.

Relief areas

Relief area is that portion of the denture that is reduced to eliminate excessive pressure on specific parts on the denture supporting tissues. If these parts are not relieved they may cause discomfort to the patient or instability to the denture when subjected to occlusal forces.

Relief areas in the maxillary arch and palate:

- Incisive papilla. • Median raphe. • Tours palatinus. • Sharp bony prominences.

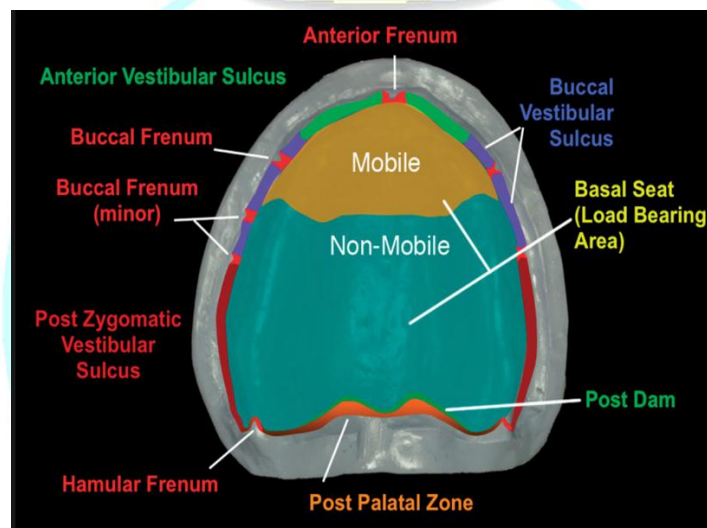
Relief areas in the mandibular arch:

- Genial tubercle. • Sharp mylohyoid ridge. • Mandibular tori. • Crest of a knife edge ridge. • Mental foramen (with flat ridge) • Sharp bony prominences.

Border structures of the dentures:

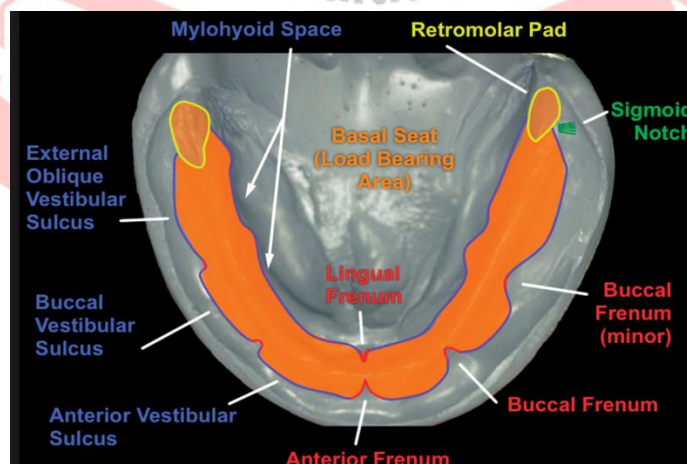
Border structure of the maxillary dentures:

1. The labial frenum
2. Labial vestibule (Labial mucous membrane reflection area)
3. Buccal frenum
4. Buccal vestibule (Buccal m.m. reflection area)
5. Hamular notch
6. Vibrating line of the soft palate .



Border structure of the mandibular dentures:

1. Labial frenum
2. Labial vestibule
3. Buccal frenum
4. Buccal vestibule
5. Retromolar pad



Chapter 3

Impression trays and materials

Outline:

- Terminology
- Requirements
- Functions
- Types of trays
- Pouring the different casts
- Requirements of a dental cast.

Terminology:

Objectives:

Impression tray :

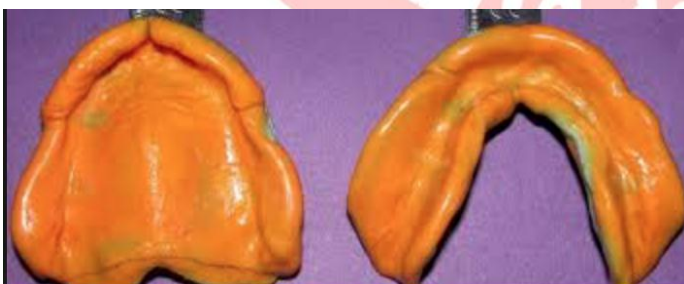Is a device used to carry, confine and control impression material while making an impression.

Impression :

An impression is an imprint or negative reproduction of an object from which a positive likeness or cast can be made.

In dental prosthetics, an impression is a negative registration of the entire denture bearing area.

An impression is made in order to reproduce a positive form of the oral tissue (cast).



For construction of complete denture two impressions are needed :

Preliminary impression :

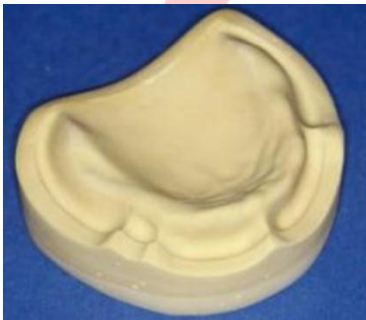It is an impression made in a stock tray for making a study cast on which a custom tray is constructed.

Final impression :

It is an impression made in custom tray and it is used for the purpose of making the master cast on which the denture is constructed.

Cast :

It is a positive reproduction of the form of the tissues of the upper or lower arch over which denture bases or other dental restorations may be fabricated.



Study (diagnostic) cast

A cast formed from a primary impression for use in diagnosis or the construction of custom tray.

Master (definitive) cast

A cast formed from a final impression and used for fabrication of the prosthesis

Impression trays

An impression tray is a device used to carry, confine and control impression materials while making an impression. carry, confine and control impression materials while making an impression. Impression trays are classified as:

Stock trays made by manufacturers and **Custom or Special trays** made specially for one patient and discarded later.

REQUIREMENTS OF IMPRESSION TRAYS:

- 1- The tray should be rigid and strong, but not too thick. A uniform thickness of 2 mm should be adequate.
- 2- The tray should simulate the finished denture in size and shape.
- 3- The border extension of the tray should be 2mm short of the vestibular depth with no interference with muscle or frenal attachments.
- 4- The entire borders of the tray should be smooth and rounded.
- 5- The tray should retain its shape through- out the impression procedure and pour- ing of the impression.
- 6- The handle of the tray should be angulated so that it aids in manipulation of the tray without distorting natural lip contours.
- 7- It should accept the desired modifications.

FUNCTIONS OF IMPRESSION TRAYS

- 1- support the impression material in con- tact with the oral tissues while making the impression.
- 2- Support the impression material while removed from the mouth and while pouring the cast.

A. Stock trays:

Stock trays are classified according to the following factors :

1- The presence of or absence of natural teeth.

a- Impression trays with flat or square floor : They are suitable for dentulous patient



b- Impression trays with round or oval floor :They are suitable for edentulous patients.



2- The nature of impression material.

Impression trays may also be classified according to the nature of impression material used into the following types.

a- Plain trays. b- Perforated trays. c- Rim-lock trays. d- Water-cooled trays.

3-Size of the dental arch

Impression trays varies in size from small, medium to large. To be suitable for different arch sizes.

4- Materials from which the stock trays are constructed

a- Metallic

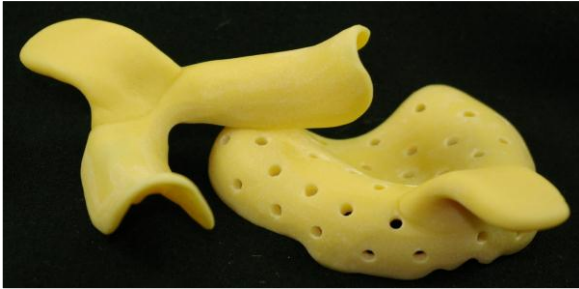- Aluminum • Stainless steel

b- non metallic

- Plastic trays which can be sterilized. • Disposable plastic trays

B. Custom trays : (Special trays)

They are designed to enable the dentist to make a more accurate and detailed impression than is possible with stock trays.



Advantages of custom trays :

1. It fits accurately the arches of the patient.
2. The bulk of the impression material is reduced and accordingly less dimensional changes will be expected.
3. Less impression material is used. 4. More comfortable to the patient.

Requirements :

- 1- The tray should be rigid and of uniform thickness (2mm).
- 2- The tray should simulate the finished denture in size and shape.
- 3- The border extension of the tray 2mm short of the vestibular depth.
- 4- The borders should be smooth and rounded.
- 5- The tray should retain its shape during the impression procedure and pouring of the impression.
- 6- It should be easily and rapidly constructed.
- 7- It should accept trimming.

Custom tray Materials :

1) Thermoplastic materials

- Shellac base plate • Modeling compound • Hydroplastic tray material.

2) Resins :

- Self cure. • Heat cure. • Light cure. • Plastic sheets.

Self-curing acrylic :

Modified methyl methacrylates are the most widely used material for making custom trays.

Advantages :

1. Easily constructed. 2. More rigid than shellac base plate trays. 3. Can accept border tracing material.

Construction of special tray:

- All apparent undercuts on the cast are blocked out with base plate wax.
- The exposed areas on the casts are coated with separating medium.
- The acrylic resin powder and liquid are mixed according to the manufacturer's instructions in a glass container. The consistency of the mix is checked periodically till it reaches the dough stage, wooden blade is used for mixing.
- The dough is placed within a form on a glass slab. It is patted out to form a wafer of uniform thickness, or two wet plastic sheets or glass plates are used to shape the dough into a wafer or sheet of suitable thickness.
- The wafer of the tray material is lifted from the slab and adapted to the cast with light finger pressure.
- A warm knife may be used to trim the soft material from around the borders of the cast, final trimming is done after curing.
- Excess material is formed into a handle of the desired shape. The handle must be placed so that it will not interfere with any movements of the patient's lips during impression procedures.

Spacer :

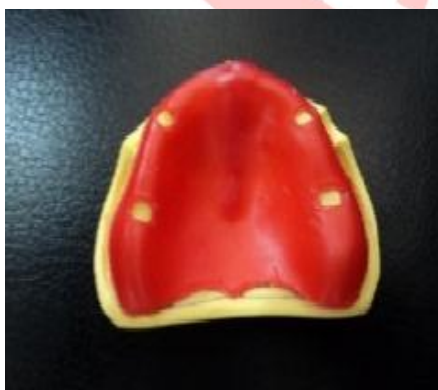Custom trays are sometimes provided with a spacer to ensure enough space between the tray and the tissues to allow an even thickness of impression material. The type of impression material used for the final impressions and impression technique determines whether a spacer is needed or not and the thickness of spacer to be used.

**Advantage of the spacer :**

- 1- It provides a space of even thickness in the custom tray for the impression material and thus any dimensional change in the material will be equal throughout the impression.
- 2- In case of plaster impression material, the suitable thickness provided will help the fractured areas to be accurately reassembled.

Methods of construction of the spacer:**The first method :**

- The outline of the impression tray is drawn on the cast using an indelible pencil. To be 2mm short of the vestibular depth. The outline for the wax spacer is drawn on the cast 2 mm. Shorter of the tray outline.
- One or two layers of base plate wax is adapted to the cast and trimmed to the previously drawn outline.
- Tissue stops are made by removing 4mm. square of wax to expose the cast in the canine and molar regions .



The second method :

- The cast is immersed in cold water for 10 minutes. Then dipped in molten wax for several times. Each dip will add a layer to the cast, three dips are sufficient. The excess wax is trimmed to leave a spacer 2.0 mm. shorter than the tray border.

Pouring the primary impression and forming the study cast

Materials used for casting

Plaster of paris :

a white, powdery, slightly hydrated calcium sulfate made by calcination of gypsum, used for making casts and models when combined with water to form a quick setting paste.

Artificial stone :

it's a modified form of plaster of paris which sets even more slowly and produces casts of improved hardness and strength.

a. Study Cast:

The study cast is produced from pouring the primary impression in either plaster or stone.

- The study or diagnostic cast is formed from a primary impression and used for diagnosis and construction of special tray.
- The materials used for making the primary impression are either compound or alginate irreversible hydrocolloid impression materials. The primary impression is poured in either plaster or stone gypsum martial.

B. Master Cast:

The master cast is poured either by in-verting the impression on a putty of stone or by boxing the final impression. Materials used for making final impressions are zinc oxide, impression plaster, impression waxes and rubber base impression materials.

Boxing of an impression :

Boxing an impression produces a container into which stone can be poured.

Advantages of boxing :

- 1- It allows preservation of the borders of the impression.

2- It allows the use of a mounting plate which in turn permits the master cast to be repositioned accurately on the articulator after the denture has been cured (Laboratory remount) .

3- It produces denser cast as it allows vibration to get rid of air bubbles.

4. Boxing produces a dense accurate master cast of a predetermined thickness.

REQUIREMENTS OF A DENTAL CAST:

1- The surface of cast should be hard, dense, clean and free of voids or nodules.

2- A cast should extend sufficiently to include all of the area available for denture support.

3- The peripheral roll should be complete and no deeper than 3.0 mm, and the edge of the cast extending out from this roll should be approximately 3.0 mm. wide

4- The side walls of a cast should be vertical.

5- The base of a cast should not be less than 10mm at the thinnest point.

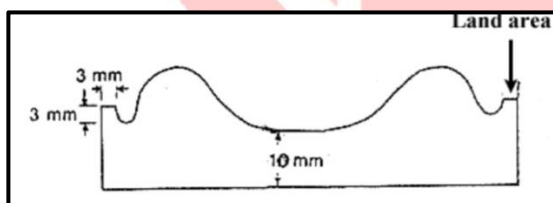
6- The tongue space on a mandibular cast should be flat and smooth when trimmed, but the lingual peripheral roll should remain intact

7- The contour of the base of maxillary and mandibular casts :

The anterior border of the maxillary cast is pointed at the midline and the anterior border of the mandibular cast is curved from canine to canine.

8- A land area of 3.0 mm should be maintained around the entire cast.

9- The base of the cast is trimmed so that the occlusal surface of the teeth or the plane of the edentulous ridge is parallel to the base.



Chapter 4

Record Blocks and Mounting

Outline:

- Functions
- Record blocks : a. Record Bases. b. Occlusion rims
- Marking the occlusion rims.

In completely edentulous situations other means must be provided to record the jaw relations, these means are the record blocks, which are generally composed of occlusion wax rims attached to a record base.

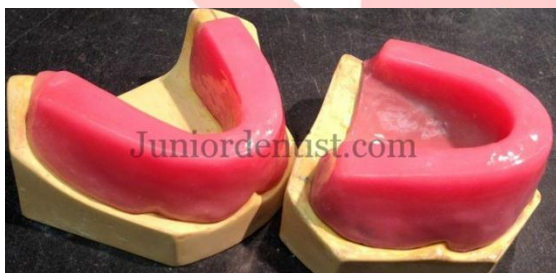FUNCTION OF THE RECORD BLOCKS

1- Jaw relations recording.

2- Selection of teeth:

- High and low lip lines help in determining the length of the anterior teeth.
- The distance between the two canine lines determines the width of the anterior teeth.
- The distance between the canine line and the posterior end of the occlusion rim determine the mesiodistal width of the posterior teeth.

3- Arrangement of teeth:



RECORD BLOCKS

Are composed of record base and occlusion rim.

I. Record base :

Requirements :

It must be reasonably rigid to withstand handling under pressure in the patient's mouth.

It must fit the cast accurately in order to keep the same relationship of the occlusal rim to the cast. An accurate base plate will result in an accurate jaw relation record.

The borders should be developed in the same manner as the borders of the finished denture.

Record bases may be temporary or permanent:

A- Temporary base :

- 1- Shellac :
- 2- Self curing acrylic resin bases:

B- Permanent base :

- 1- Heat cured acrylic resin bases:
- 2- Cast bases : They are either gold or chrome cobalt.

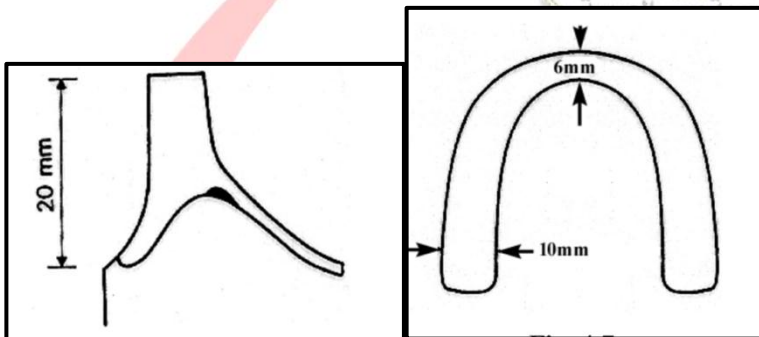
II- Occlusion Rims :

Occlusion rims are horseshoe shaped blocks of wax which are attached to the base plate. They are occluding surfaces constructed on temporary or permanent denture bases to be used in recording jaw relations and for arranging teeth.

Requirements :

1. The occlusion rim must be constructed from a material that is easy to manage.
2. It should be well attached to the underlying base.
- 3- It must be placed directly over the ridge.
- 4- It should follow the form of the arch.
- 5- It should have a smooth surface, and blend smoothly with the facial and lingual surfaces of the trial base.

- 6- The sides of the occlusion rim should make a 90° angle with the occlusal surface.
7. Its width must be considerable to permit occlusion of the upper and lower occlusion rims.
8. The posterior border of the upper rim should terminate at the anterior aspect of the maxillary tuberosity. While that of the lower rim should terminate anterior to the retromolar pad.
9. On average, the labial surface of the upper rim should be 10mm anterior to the incisive papilla.
10. The average height of the upper occlusion block is about 20mm measured from the depth of the labial frenum to the incisal edge of the upper occlusion rim.



MARKING THE OCCLUSION RIMS:

Marks or lines are marked on the record blocks during jaw relations recording which will aid in the selection and arrangement of artificial teeth, these lines are:

a-Central line or midline

This line is marked on the upper occlusion rim below the center of philtrum or at the bisection of the line from corner to corner of the mouth.

b-Canine lines

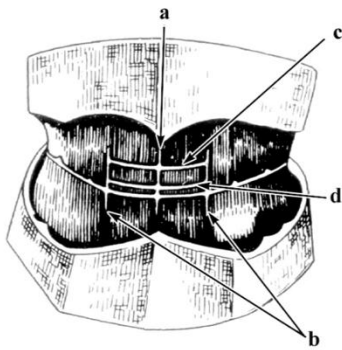
These lines mark the corners of the mouth when the lips are relaxed.

c-High lip line

The greatest height to which the lip raised in normal function or during the act of smiling broadly.

d-Low lip line

The lowest position of the inferior border of the upper lip when it is at rest, or, the lowest position of the superior border of the lower lip during smiling or voluntary retraction.



Ministry of Health & Population

وزارة الصحة والسكان

Chapter 5

Articulators

The information obtained from the cast, occlusal rims and bases may be termed static information, but, the mouth is a dynamic system, therefore, some means should be available in the laboratory for converting static information into a dynamic form. This is done by mounting the casts on an instrument called an articulator.

TERMINOLOGY

Mounting :

A laboratory procedure of attaching the maxillary and or the mandibular cast to an articulator or similar instrument.

Articulator :

An articulator is a mechanical instrument that represents the temporo mandibular joints and jaws, to which maxillary and mandibular casts may be attached to simulate some or all mandibular movements.

Condylar guidance :

The mechanical device on an articulator intended to produce similar guidance in articulator movement as are produced by the paths of the condyles in the TMJ.

Incisal guidance :

The part of the articulator that maintains the incisal guide angle.

FUNCTIONS

1. The primary function of the articulator is to act as a patient in the absence of the patient.
2. Articulators can simulate, but they cannot duplicate, all the possible mandibular movements.
3. Mounting dental casts for diagnosis and treatment planning.

4. Fabrication of occlusal surfaces for dental restoration.
5. Arrangement of artificial teeth for complete and removable partial dentures.

ADVANTAGES :

1. Visualization of the patient's occlusion especially from the lingual side.
2. Patient cooperation is not a factor once the appropriate inter occlusal records are obtained from the patient.
3. Considerable chair time and patient appointment time is saved.
4. The patient's saliva, tongue, and cheeks are not factors when using an articulator.

REQUIREMENTS :

Minimal articulator requirements:

1. The articulator must accurately maintain the correct horizontal and vertical relationship of the patient's casts.
2. The casts must be easily removed and attached to the articulator without losing their correct relationship.
3. The articulator should have an incisal guide pin with a positive stop to preserve the patient's vertical dimension.
4. The articulator should be able to open and close in a hinge like fashion.
5. The construction should be accurate, rigid, and of non-corrosive material.
6. The moving parts should resist wear. The adjustment should be able to move freely and be definitely secured. The articulator should be stable on the laboratory bench and not too bulky and heavy.

CLASSIFICATION :

Articulators are classified according to the instrument capability and record acceptance into :

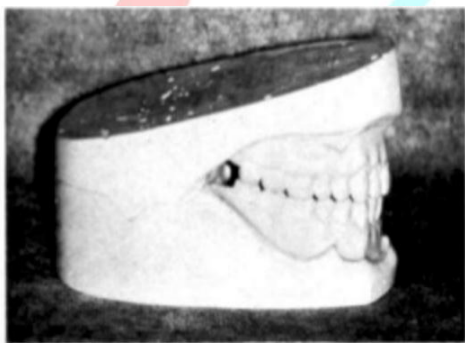
Class I :

Simple holding instruments :

Instruments in this class accept a single inter-occlusal record (centric relation) vertical motion may or may not be possible. The first articulator was a plaster slab articulator followed by a simple hinge articulator.

A- Plaster slab articulator : (Relator)

It was formed by extending plaster index from the rear of the casts. The casts were keyed to each other by means of their indices.



B- Simple hinge articulator : (Plane line)

This articulator produces the simple opening and closing movements of the TMJ. It consists of two bows united by a hinge and a posterior screw adjustment that can raise or lower the distance between the bows.



Class II :**Mean value articulators :**

These articulators have two jaw members, joined by two joints representing the TMJ. These articulators are capable of eccentric movement, but the condylar path here is fixed at a certain angle, which is the average for many patients. It ranges from 30° - 40° from the horizontal. The incisal guidance may be fixed to an average or may be adjustable.

This type of articulator can be used with or without face bow record. The upper cast can be mounted either by face bow record or according to an average making use of the Bonwill triangle.

Bonwill triangle makes an angle with the occlusal plane with an average of 15 degree called Bonwill angle.

**Class III :****Adjustable condylar path articulators**

This class of articulators differs from the fixed condylar path articulators in that they can accept eccentric records that are used to adjust the condylar guidance of the articulator.

According to the eccentric records accepted by these types of articulators, they are classified into :

Semi and fully adjustable condylar path articulator.

A- Semi adjustable condylar path articulator :

This type of articulator can accept the following records :

1. Face bow record to mount the upper cast.

2. Centric relation record to mount the lower cast.

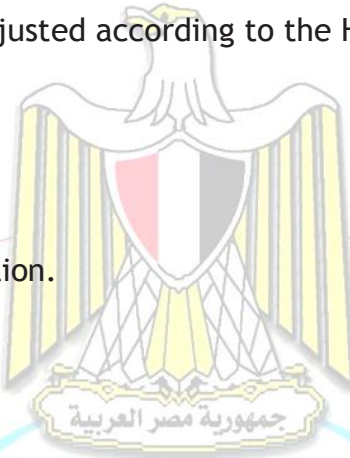3. Protrusive record, to adjust the articulator's horizontal guidance, that correspond to the patient's horizontal condylar path inclination.

The lateral condylar guidance is adjusted according to the Hanau's formula.

$$L = H/8 + 12$$

L : The lateral condylar inclination.

H : The horizontal condylar inclination.



B- Fully adjustable condylar path articulators : This type of articulators accept the following records :

1. Face bow record to mount the upper cast.
2. Centric relation record to mount the lower cast.
3. Protrusive record, to adjust the articulator's horizontal condylar guidance which corresponds to the patient's horizontal condylar path inclination.
4. Right lateral record, to adjust the right lateral condylar guidance.
5. Left lateral record, to adjust the left lateral condylar guidance.



Chapter 6

Arrangement of Artificial Teeth

Outline:

- Occlusal curvatures.
- General consideration for the arrangement of teeth.
- Guides used for arranging artificial teeth Sequence of arrangement of teeth

The arrangement of artificial teeth must be physiological and esthetically acceptable. Physiologically, they must be in a position compatible with the lips, tongue, and cheeks whether the mandible is in a relaxed position, or in motion, the teeth must function in harmony with the surrounding oral environment in functional and parafunctional mandibular movement and must be acceptable to the patient.

The placement of each tooth, and the reason why it is so placed must be understood, because if each tooth is not positioned and angulated correctly, the dentures will be functionally inefficient and esthetically poor.

Terminology:

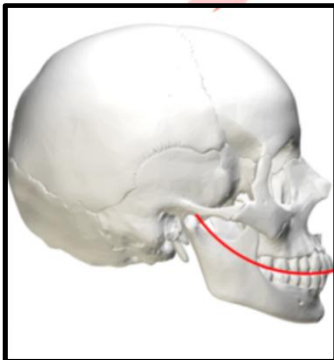
Balanced occlusion

The simultaneous contacting of the upper and lower teeth as they glide over each other when the mandible is moved from centric relation to eccentric relations.

OCCUSAL CURVATURES

Occlusal curvatures or curves of occlusion : This is a curved occlusal surface that makes simultaneous contact with the major portion of the incisal and occlusal prominences of the existing teeth.

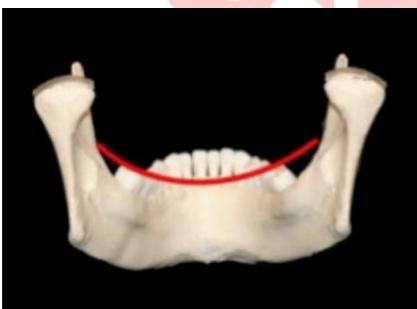Anteroposterior curve (Curve of Spee)



It is the anatomical curvature of the occlusal alignment of the teeth beginning at the tip of the lower cuspid and following the buccal cusps of the natural bicusps and molars and continuing to the anterior border of the ramus. It conforms to an arc of a circle of 7 cm radius its center is at the crista lacremalis posterior .

Lateral Curve (Curve of Monson) :

The curve of occlusion in which each cusp and incisal edge touches or conforms to a segment of the surface of a sphere 20 cm in diameter with its center in the region of the glabella.



Compensating curves :

Compensating curves are the artificial curves introduced into dentures in order to facilitate the production of balanced occlusion; they are artificial counter-parts of the curves of Spee (anteroposterior) and Monson (lateral) which are found in the natural dentition.

GENERAL CONSIDERATIONS FOR THE ARRANGEMENT OF TEETH :

1. Maxillary teeth :

Anterior teeth

Three important factors must be considered when arranging anterior teeth :

a. Esthetics :

In order to restore the natural looking and contour of the facial structure, it is important to notice the shape and contour of the lips, mouth, and muscles of facial expression, as these depend on the positioning of the teeth and the contour of the base.

b. Phonetics :

Speech is affected by the position of the teeth, the contour and bulk of the denture base material about the lingual aspect of the teeth, and the thickness of the palate.

Posterior teeth :

Four important factors must be considered when arranging posterior teeth.

a. The crest of the lower ridge:

The arrangement of upper posterior teeth is governed by the position of the crest of the lower ridge. The central groove of each upper posterior tooth is placed parallel to and directly over this crest. The crest of the lower ridge is indicated by a straight line drawn on the cast

b. Common horizontal plane:

The occlusal surfaces of the right and left posterior teeth must be on the same horizontal plane or level.

c. Spacing of posterior teeth :

The posterior teeth are arranged with a broken contact. The distance between the canine and first premolar is 0.5 mm. The other posterior teeth are spaced by about 0.25 mm in order to:

- Permit change in position of upper posterior teeth when arranging the lower posteriors to articulate with them.
- Prevent a crowded arrangement that might make it difficult to position the lower first premolar.
- Permit slight tooth movements brought about by pressure created during packing and processing of acrylic resin.

2. Mandibular teeth:

Anterior teeth

In arranging lower anterior teeth esthetics, phonetics, and incision must be considered as in upper anterior teeth.

Posterior teeth

The mandibular posterior teeth must be arranged to contact the maxillary posterior teeth in a balanced occlusion to obtain equilibrium of the denture.

SEQUENCE OF TEETH ARRANGEMENT:

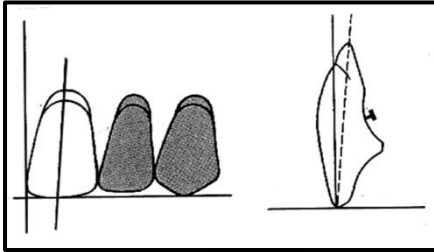
The sequence in which artificial teeth are arranged is not as important as the end result. There are many acceptable methods for arranging artificial teeth. Most of these methods begin with the arrangement of the maxillary central incisors, as they maintain the central line, the remaining maxillary anteriors are then arranged in sequence.

One of the popular sequences of arrangement is to set all the maxillary teeth first, then the mandibular posteriors starting with the second premolar placed to occlude with the upper 4 and 5 and lastly the mandibular anteriors.

Positions of the upper teeth:


The central incisor :

Its long axis is parallel to the vertical axis or inclined slightly to the distal when viewed from the front, and sloping slightly labially when viewed from the side. The incisive edges are in contact with the occlusal plane.



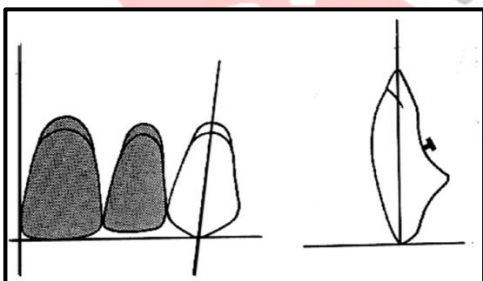
The lateral incisor :

Its long axis is inclined distally when viewed from the front, and inclined labially when viewed from the side. The neck is depressed although the labial surface will be nearly in line with the central incisor. The incisive edge is 0.5 to 1mm above and parallel to occlusal plane.

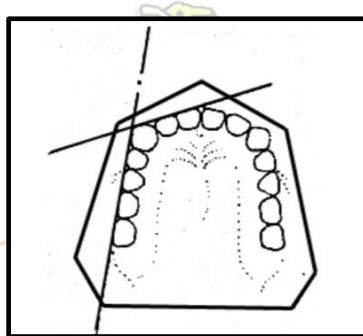


The canine :

Its long axis may be parallel or slightly distally inclined to the vertical axis when viewed from the front, and vertical when viewed from the side.



Its cusp tip is in contact with the occlusal plane. The neck is prominent as it forms the corner of the patient's mouth. The canine has two planes on the labial surface. The mesial plane should follow the contour of the anterior teeth, while the distal plane should be in line with the posterior teeth.



The first premolar :

Its long axis is parallel to the vertical axis when viewed from the front and side. The buccal cusp is raised nearly 1/2 mm from the occlusal plane, while the palatal cusp touches the occlusal plane.

The second premolar :

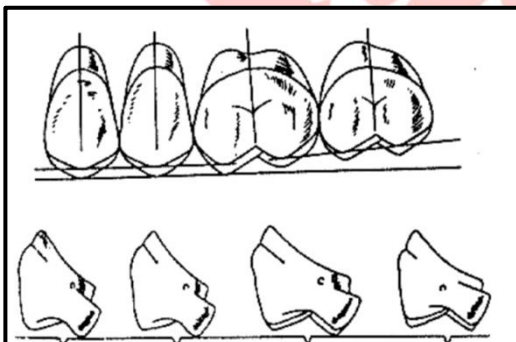
Its long axis is parallel to the vertical axis when viewed from the front and side. The buccal cusp is raised nearly 0.5 mm while the palatal cusp touches the occlusal plane.

The first molar :

Its long axis is inclined slightly to the mesial when viewed from the front. The mesiopalatal cusp is the only cusp in contact with the occlusal plane.

The second molar :

Its long axis is inclined to the mesial when viewed from the front. All the four cusps are short of the occlusal plane, but the mesiopalatal cusp is the closest to it.



Positions of the lower teeth :

The central incisor :

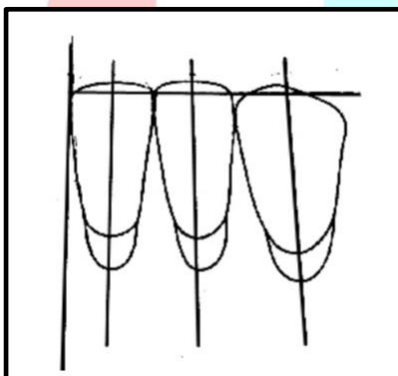
Its long axis is parallel to the vertical axis when viewed from the front and slopes labially when viewed from the side. The incisal edge is parallel to and 1mm above the occlusal plane, to establish vertical overlap of the maxillary anteriors.

The lateral incisor :

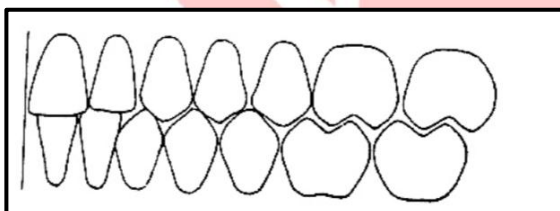
Its long axis is parallel to the vertical axis or inclined slightly to the mesial when viewed from the front. While from the side, it is inclined labially. The incisal edge is parallel to, and also 1mm above the occlusal plane.

The canine :

Its long axis leans slightly towards the midline when viewed from the front. While very slightly lingually, when viewed from the side. Its cusp tip is at the same plane as the incisal edges of the central and lateral incisors 1mm above the occlusal plane to establish vertical overlap of the maxillary anteriors.



The mandibular posterior teeth must be arranged to contact the upper posterior teeth without interference (balanced occlusion).



Chapter 7

Complete Denture Processing

Outline:

- Wax contouring.
- Flasking.
- Boil out.
- Packing of acrylic resin.
- Curing.
- Deflasking and Remounting.
- Finishing and Polishing.

The objective of processing denture is to duplicate the trial dentures into a hardened polished plastic material.

WAX CONTOURING (FESTOONING)

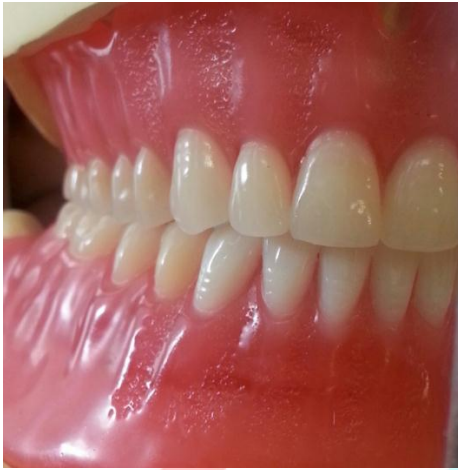Wax contouring is the process of carving the denture base to simulate the contour of the natural tissues that are being replaced by the denture. The gingival portion of a complete denture is carved to simulate natural gingival contour.

These carvings are made in wax after the teeth have been arranged. The term festooning is used to differentiate waxing a denture base from making wax patterns for cast metal restorations.

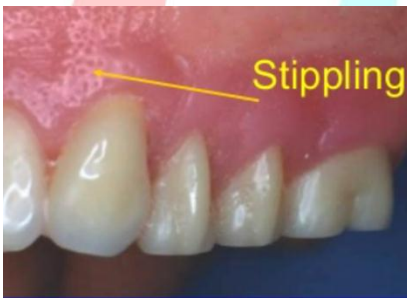Objectives :

- To produce a pleasing natural appearance.
- To aid in retention and stability of the denture.

The most desirable procedure is to carve the trial denture as exactly as possible to the final shape and bulk in wax so that only minimal finishing and polishing are required. Minimal palatal thickness should be 2.5 mm (two layers of base plate wax warmed and adapted to the cast).



Stippling the facial surface of the denture to simulate natural gums can be easily accomplished by the application of a stiff brush .



Maxillary denture :

- The labial surface is determined by the esthetic requirements of the case.
- The buccal surface should look outwards and downwards.
- The palatal surface will look inwards and downwards.

Mandibular denture :

- The labial surface is relatively straight.
- The lingual anterior surface is relatively straight.
- The buccal surface in the premolar region must be thin to avoid the modiolus lifting the denture. Modiolus is the point of connection of the facial muscles to the orbicularis oris muscle.

- The buccal surface in the molar region looks outwards and upwards.
- The lingual surface looks inwards and upwards.

FLASKING : (INVESTING THE DENTURE)

Flasking is the process of investing the cast and trial denture in a flask to make two sectional mold.

Compression molding technique:

- The festooned wax denture must be converted to resin to make a denture. This is done by using the wax denture as a pattern to make a mold, into which the denture base resin is inserted and cured.

Procedure :

- The cast and mounting is soaked in water for not more than 5 minutes otherwise the surface becomes etched.
- The cast is separated from the plaster articulator mounting. The plaster mounting must be saved as it will be used to reposition the cast on the articulator after denture processing.
- The wax denture base is invested in a dental flask and then the wax is eliminated, forming a mold into which methyl methacrylate resin is packed. After the resin is cured, the denture is removed from the flask, finished and polished.
- The inside of the flask is coated with vaseline.
- The cast is painted with plaster separating medium (liquid soap or vaseline) to act as separator.
- Stone is mixed and placed in the base of the flask. The cast is pushed to place till it touches the base of the flask. The borders of the cast must be in level with the edges of the flask and the occlusal plane approximately parallel to the base of the flask
- A plaster separator is painted on the stone.
- The upper half of the flask is put in place and the flask is checked to be sure that the teeth do not protrude above the top of the flask.

- The second mix is poured over the teeth till the occlusal surface of the invested teeth. The stone is wiped off the occlusal surfaces of the teeth leaving the teeth exposed.
- The stone is allowed to set.
- A separating medium is painted and the third mix is placed in the flask. This is referred to as capping. The lid placed on the flask and tapped firmly to place.

BOIL OUT : (WAX ELIMINATION)

- After the flasking and complete setting of the stone, the flask is placed into boiling water for 5 minutes, this will soften the waxed denture base, which can then be easily removed from the mold when the flask is opened.
- The flask opened by inserting plaster knife between the two halves of the flask. The wax denture is removed from the mold in one piece.
- All the teeth should remain in the top half of the flask, any pulled teeth should be replaced back into place.
- The opened flask is placed in the hot water until the remaining wax is removed.
- Wax solvent is applied around the teeth, hot water is used to remove all traces of the wax solvent. Acrylic resin will not adhere to a surface coated with wax.
- The flask is placed on its side to allow water to drain from it.
- After the mold and the teeth have dried, any loose tooth must be cemented to its place.

PACKING OF ACRYLIC RESIN

- Enough material must be used to ensure over packing on the first closure. A piece of wet cellophane is placed over the resin before the flask is assembled. This allows the flask to be reopened for inspection and add or remove resin without having the cast adhere to the tissue surface of the uncured resin.
- The lower half of the flask is placed in position on the upper half and pressed by hand then placed in bench press and closed slowly to give the acrylic resin plenty of time to flow.

- The flask is removed from the press, opened carefully, the excess acrylic resin is trimmed with a shape carver or scalpel .
- The upper and lower halves of the flask are assembled and the two flasks are placed in the processing press the flasks should be allowed to stand for 30-60 minutes before curing.

CURING OF ACRYLIC RESIN :

Curing cycles

Most denture resin are cured by one of two cycles :

Long cycle (Slow processing) 9 hours at a constant 70° C.

Short cycle (Rapid processing) 70° C for 1.5 hour then boil for 30 minutes

DEFLASKING OF DENTURES :

- After the dentures are cured, the flasks must cool to room temperature before they are removed from the processing press.
- The lid of the flasks removed.
- An alternate method is by using a hammer to strike the knock-out plate on the bottom of the flask. The base part of the flask is removed followed by the top part.
- A knife blade is placed at the junction between the stone cap and the rest of the stone to separate it and expose the cusp tips and incisal edges of the teeth.
- The stone sections are separated gently, then the stone is removed from the palate or tongue area using a knife. The denture must be kept on the cast, care must be taken to ensure that the casts are not broken.
- A tooth brush is used to clean the index grooves on the base of the cast to facilitate accurate repositioning of the casts on the mounting plaster for the correction of any processing errors.

FINISHING COMPLETE DENTURE

The finishing of denture consists of perfecting the final form of the denture by removing :

1. Any flash of acrylic resin at the denture border.
2. Any flash and stone remaining around the teeth.
3. Any nodule of acrylic resin on the surface of the denture base.

Polishing complete denture

Polishing of denture consists of making a denture smooth and glossy without changing its contour.

The polishing of dentures consists of making the denture surface which is in contact with lips, cheek and tongue (polished surfaces) smooth and glossy to avoid abrasion of the delicate mucous membrane in these areas.



References:

1. Stewart KL, Kuebker WA, Rudd KD: Clinical removable Prosthodontics. Third edition. Quintessence publishing Co, Chicago 2003.
2. Winkler S. Essentials of complete prosthodontics, Third Edition. WB Saunders Company, 2003.
3. Zarb GA, Bolender CL, Carlsson GE. Boucher's Prosthodontic treatment for edentulous patients, Eleventh Edition. St Louis; CV Mosby CO, 1997.
4. Rahn AO, Heartwell CM. Textbook of complete dentures. Fifth Edition. Philadelphia ; Lea and Fibiger, 1993.
5. SH Soratur . Essentials of Prosthodontics . First Edition; JAYPEE BROTHERS ,2006
6. www.qualitysafety.bmj.com
7. www.google.com
8. www.pubmed.com
9. www.biomed.net

Book Coordinator ; Mostafa Fathallah

General Directorate of Technical Education for Health

Ministry of Health & Population
وزارة الصحة والسكان